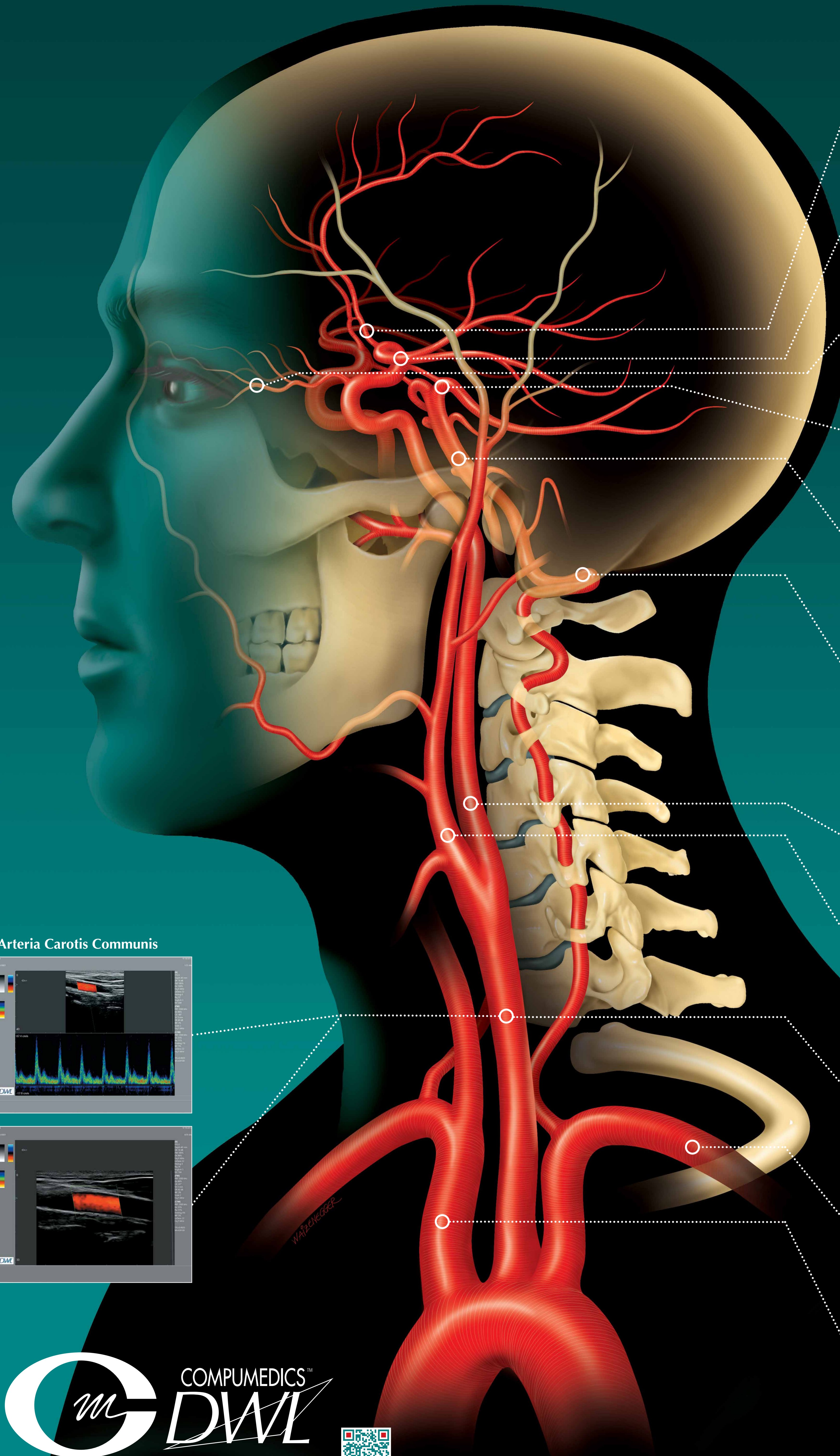
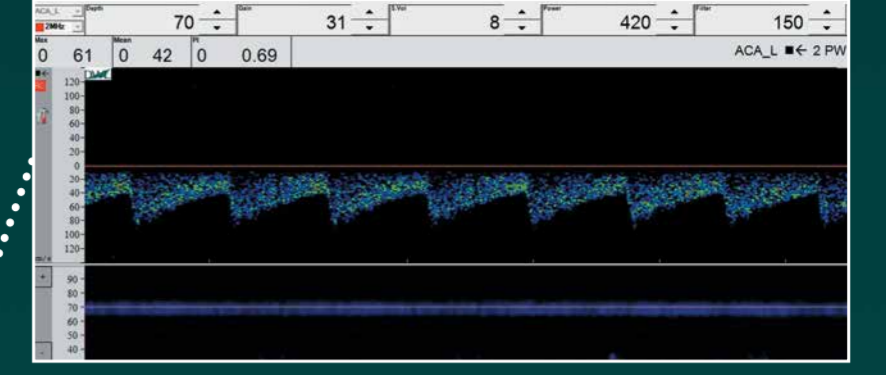


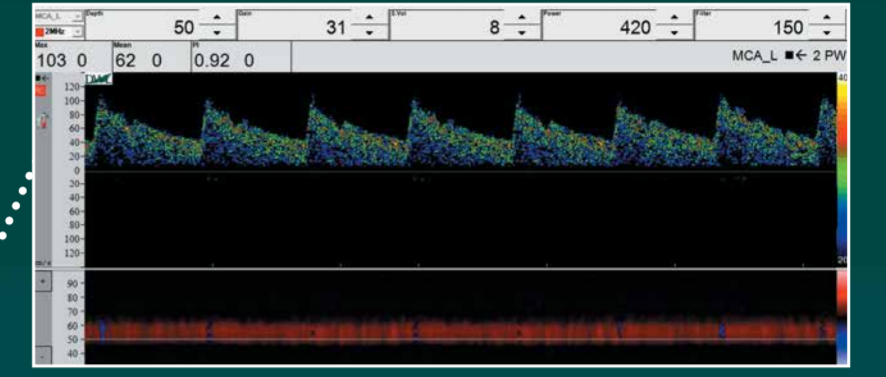
# Doppler Sonography



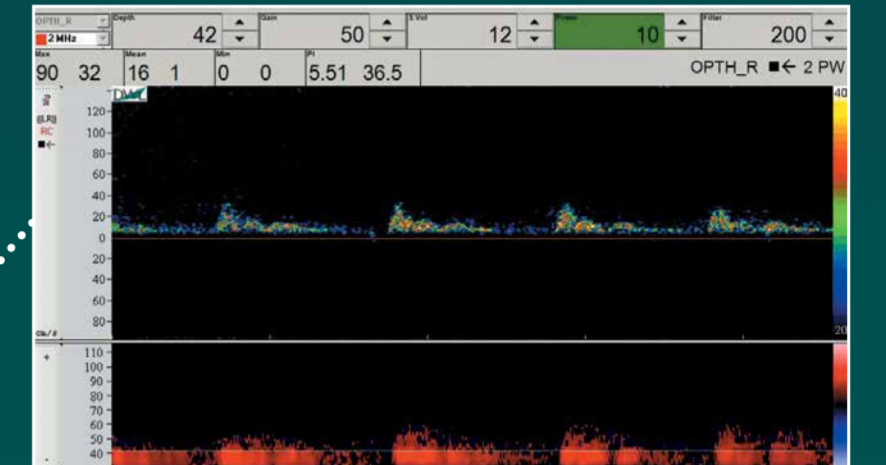
**Arteria Cerebri Anterior**  
→ 60-80 mm 50 +/- 11 cm/sec



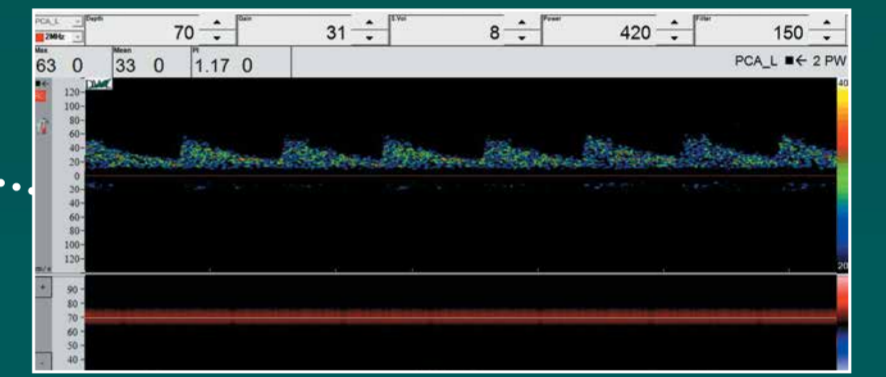
**Arteria Cerebri Media**  
← 30-60 mm 55 +/- 12 cm/sec



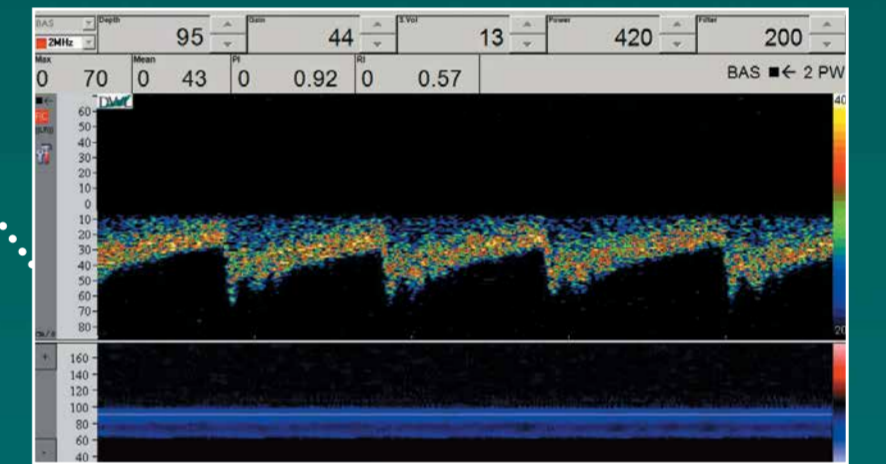
**Arteria Ophthalmica**  
← 40-60 mm 21 +/- 5 cm/sec



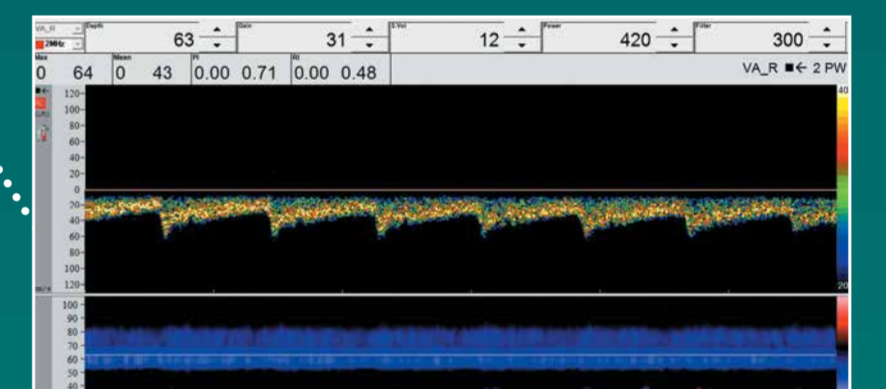
**Arteria Cerebri Posterior**  
← 60-70 mm 39 +/- 10 cm/sec  
→ 60-70 mm 40 +/- 10 cm/sec



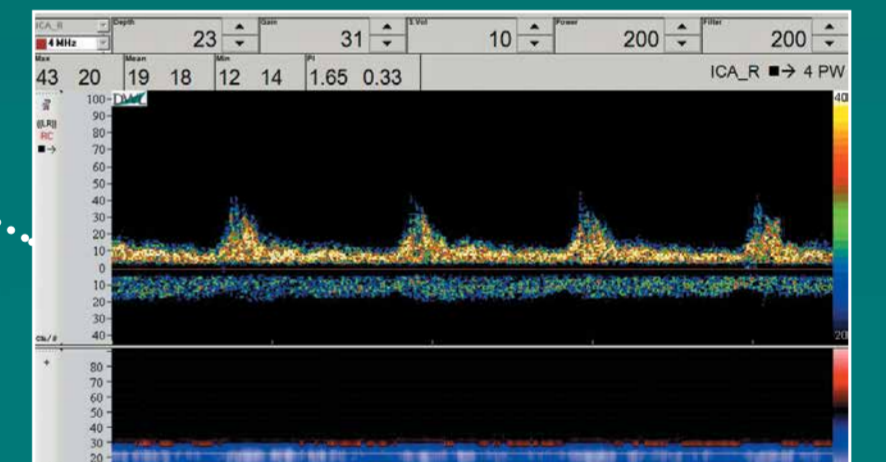
**Arteria Basilaris**  
→ 80-120 mm 41 +/- 10 cm/sec



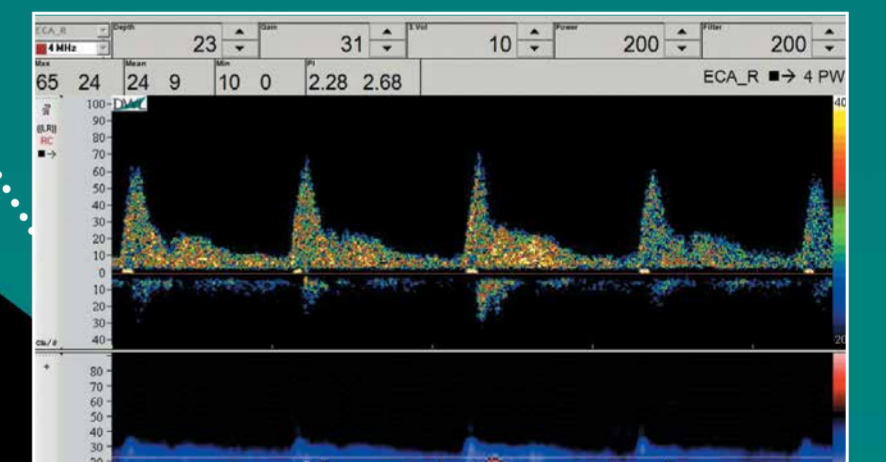
**Arteria Vertebralis**  
→ 60-90 mm 38 +/- 10 cm/sec



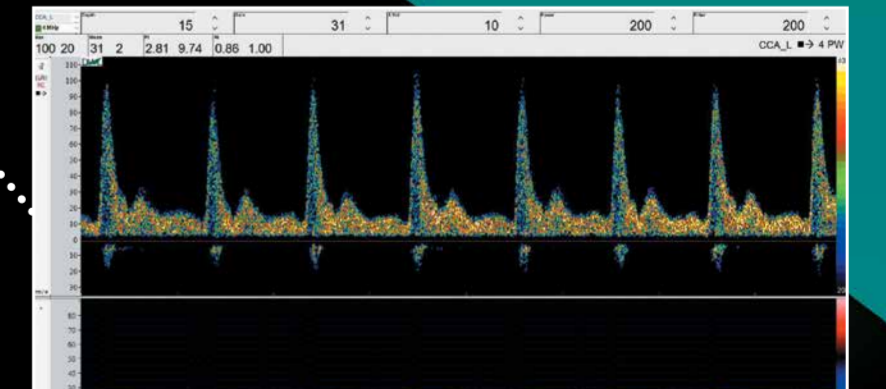
**Arteria Carotis Interna**



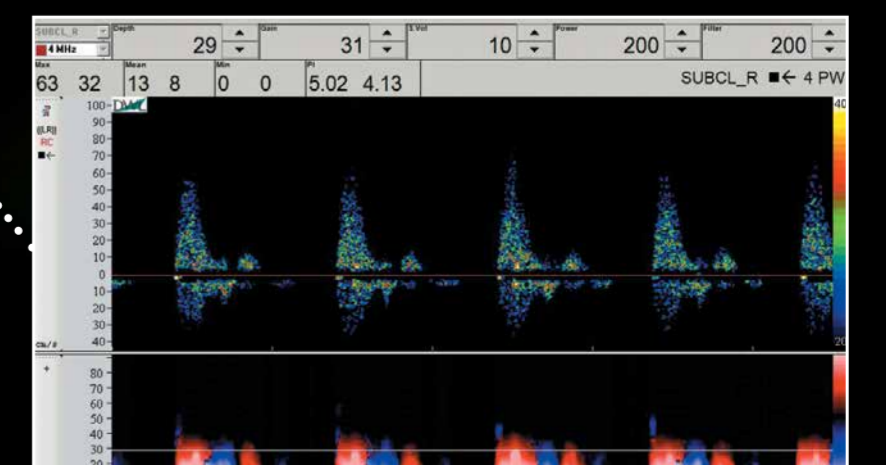
**Arteria Carotis Externa**



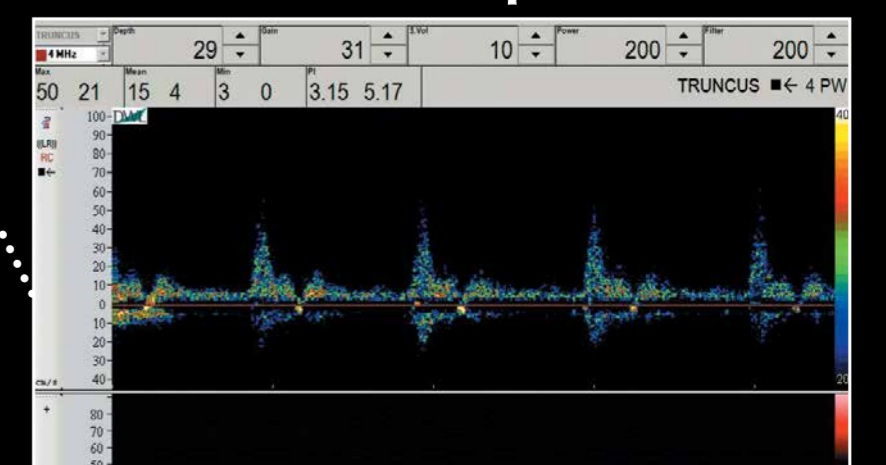
**Arteria Carotis Communis**



**Arteria Subclavia**



**Truncus Brachiocephalicus**



**Arteria Carotis Communis**

